



Paraovarian Cyst in Repeat-breeder Buffalo heifers: Ultrasonographic, Antioxidants and Serum Cell-free RNA markers

Mohamed M.M. Kandiel¹, Karima Gh. M. Mahmoud^{2*}, Sally Ibrahim², Abdelaziz. M. Sakr³, Mohamed M. Hegazy³, Amal R. Abd El Hameed² and Ahmed S.A. Sosa²

¹Department of Theriogenology, Faculty of Veterinary Medicine, Benha University, Kaliobeya, Egypt.

²Department of Animal Reproduction & AI, National Research Centre, Dokki, Tahrir Street, 12622 Giza, Egypt.

³Department of Biotechnology, Animal Production Research Institute, Egypt.



CrossMark

THIS study aimed to (1) identify the status of reproductive tract of repeat-breeder heifers (RBH) ultrasonography, as well as (2) determine the variations in steroid hormones, oxidative stress biomarkers, and cell-free RNA in serum. These culled animals from 400 heifers at the breeding station were examined ultrasonography, and whole blood samples were collected. The ultrasonic diagnosed heifers as paraovarian cyst (POC, n=18) associated with genital pathological conditions were compared with groups of control heifers at follicular (n=6), luteal (n=6), and early pregnant (n=10). The POC appeared as anechoic circumscribed masses located nearby, but separated from the ovary. Follicular number, corpus luteum size, serum cell-free RNA, and ovarian steroids were not affected by POC, although dominant follicle size tended to be lower ($P=0.069$) in POC with CL absence (POC-CL). Heifers with POC-CL had lower MDA levels than pregnant ones. Buffaloes that had POC in the presence of CL (POC+CL) were found to have higher SOD activity than luteal and pregnant cases. Total serum protein levels recorded lower values in POC+CL compared to that in follicular phase. There was a significant positive relationship between POC size, and GPx activity and CL size, but negative correlations with dominant follicles size. The POC might interfere with ovarian function, via alterations in antioxidant levels.

Keywords: Paraovarian cyst; Repeat-breeder buffalo heifers; Ultrasound; Antioxidant; Serum cell-free RNA

Introduction

Knowledge about reproductive disorders in buffaloes is necessary due to its intimate relationship with animal reproductivity and productivity. Pathological conditions disrupting ovarian functions are the highest among the abnormalities of reproductive organs present in buffaloes.

A repeat breeder is generally defined as any cow that has not conceived after three or more services associated with true estrus [1]. In buffaloes, the incidence of repeat breeding is low,

although in different publications the incidence varied from 0.70% to 30% [2]. In field, both of anestrus as well as repeat breeding are the two major reasons of reproductive disorders in buffaloes [3].

The incidence of paraovarian cysts (POC) in buffaloes varies from 0.43-13.0% [4-9]. It was stated that the incidence of POC was the highest recorded among ovarian affections in culled infertile buffaloes (13.74%), with the lowest incidence of luteal and follicular cysts (1.53 and 0.76%, respectively) [8]. Many

authors assumed the low significance of POC in relation to buffalo fertility. Nevertheless, POC in other species like ewes causes infertility due to compress the uterine tube or close the opening of oviduct fimbria [10-11].

Peri-ovarian or para-ovarian cysts are fluid-filled structures in the vicinity of ovaries that varied in size from a few millimetres to that of a modest-sized follicle [12]. The cysts arise from mesothelial, mesonephric (Wolffian) or paramesonephric (Müllerian) structures contiguous normal ipsilateral ovary [13]. The POC are considered remnants of the mesonephric ducts. They are usually found at either the cranial or caudal pole of the ovary (epoophoron and paraophoron cysts) and emerging from either the cranial or caudal sections of the mesonephric tubules [14]. Furthermore, POC may sometimes be mistaken for cystic ovary on rectal palpation because of closeness to the ovary. The difference in detection of POC pre-slaughter per rectum and after slaughter reaches to 5% [8]. They are occasionally found around the ovary and fallopian tubes, attached in the broad ligaments of cows and buffaloes [15]. The POC can be near the fimbria, alongside the uterine tubes, inside the broad ligament or mesosalpinx [10,16,17]. Tiny paraovarian cysts of few millimetre diameters are incidental findings in slaughtered buffaloes [18]. The cysts may vary in size from 1 to 5 cm in diameter and are usually round or oval in shape [9].

A proper balance between reactive oxygen species (ROS) that generate as by-products during different ovarian physiological process and antioxidants are essential for optimal ovarian functions during entire reproductive life in females [19]. Oxidative stress is known as one of the most common mechanisms associated with natural events as pregnancy [20] and a variety of diseases [21]. It was shown that catalase (CAT), glutathione peroxidase (GPx), total antioxidant capacity (TAC), super oxide dismutase (SOD), and the lipid peroxide (malondialdehyde, MDA) play an important roles in ovarian functions (folliculogenesis, ovulation, and different luteal phases) [19].

Recently, serum cell-free RNA is known as key player for regulation of gene expression in different physiological conditions, and any alterations in their expression may be associated with pathological disorders [22]. Moreover, serum cell-free RNA has the potential to serve as

biomarker for several medical conditions, because of their high stability [23]. However, limitations in the isolation methods of serum cell-free RNA, as well as a lack of knowledge on factors, which may affect recovery rate of serum cell-free RNA from different biological samples, can hinder their successful discovery [24]. Many studies reported that serum cell-free RNA is a potential biomarker for diagnosis of ovarian endometriosis [22, 25, 26].

Little is known about the changes in antioxidant parameters and serum cell-free RNA concentrations that may be associated with POC in buffaloes. The hypothesis is the serum cell-free RNA is associated with the disease and POC is neither a major nor a secondary cause of infertility in buffaloes. We need to explain the association of POC with infertility in the reported buffalo heifers. Therefore, the current study aimed to (1) identify the status of reproductive tract of repeat-breeder heifers by ultrasonography, as well as (2) investigate the variations in ovarian structures, steroid hormones {estradiol (E2) & progesterone (P4)}, oxidative stress biomarkers (CAT, GPx, SOD, TAC, and MDA), and serum cell-free RNA, in these culled buffalo heifers.

Materials and Methods

Animals

This study was carried out on eighteen POC non-pregnant buffalo heifers (*Bubalus bubalis*) aged more than three years. The heifers were excluded from breeding during routine examination by ultrasonography pregnancy diagnosis from 400 heifers. By repeating examination, they reported as non-pregnant and all were repeat breeders. These heifers belonged to a breeding station at Mahalet Mussa near to Sakha, Kafr El-Sheikh Governorate. All pregnant and non-pregnant heifers were subjected to the same management and nutrition programs. Blood samples were collected for measuring serum P4 and E2 hormones, TAC, MDA, GPx, SOD, CAT, total proteins and serum cell-free RNA. Ethical considerations during blood samples were followed according to National Research Centre Committee.

Ultrasound examination

Ultrasonographic examination was conducted per rectum in all buffaloes prior to blood sampling, using Sonoscape A6V supplied with 2-12 MHz linear transducer [27]. To identify POC properly, ovarian boundaries and its parenchyma were delineated, and POC appeared as

an anechoic structure located alongside the ovary [28]. According to ovarian findings by ultrasound; the animals were classified into: POC with no CL (corpus luteum) on the ovaries (POC-CL; n=10) and POC with CL on the ovaries (POC+CL; n=8), and were compared with groups of control heifers at follicular (n=6), luteal (n=6) and two months pregnancy (n=10). The association of POC with pathological conditions in the genital system (Vaginitis, cervicitis, endometritis, salpingitis, and oovaritis) is illustrated in Table (1).

Measurement of ovarian steroid hormones in serum

The concentrations of P4 and E2 hormones were determined in serum, using commercial ELISA kits (ChemuxBioScience, South San Francisco, USA) as indicated by the manufacturer's instructions. The value of optical density (OD) was checked, using ELISA microplate reader (BioTek ELx800, Vermont, USA), at 450 nm wavelength for both steroidal hormones.

Measurement of antioxidants and total protein in serum

The level of TAC was determined colorimetrically via commercial kit (Biodiagnostic, Egypt) as recorded by Koracevic et al. [29]. The MDA level was measured colorimetrically, using commercial kit (Biodiagnostic, Egypt) according to the method of Ohkawa et al. [30]. The activity of GPx and SOD was estimated kinetically, using commercial assay kits (Biodiagnostic, Egypt) according to Paglia and Valentine [31], and Nishikimi et al. [32], respectively. Total proteins were measured colorimetrically by Biuret method via a commercial kit (Biodiagnostic, Egypt) indicated by Gorna et al. [33].

Serum cell-free RNA

For purification of cell-free total RNA, we used a miRNeasy serum/plasma kit (Qiagen). 200 µl of thawed serum samples on ice were used for purification cell-free total RNA according to manufacturer's protocol. During purification steps, 3.5 µl of lyophilized *C. elegans* miR-39 miRNA mimic (miRNeasy Serum/Plasma Spike-In Control) were added, at concentration 1.6×10^8 copies/µl (working solution). In order to elute RNA, 14 µl of RNase-free water was added to the centre of the spin column membrane. Afterwards, the purified cell-free total RNA was kept at -80°C for further processing. The concentration of total RNA was checked by Nano-drop 2000/c (Thermo Fisher Scientific, Wilmington, USA), and also the RNA integrity was evaluated by denaturing agarose gel electrophoresis and ethidium bromide staining.

Statistical analysis

The obtained data were tabulated, presented as mean \pm Standard error of means (SE), and statistically analyzed with IBM SPSS version 21. Data were analyzed statistically using Mann-Whitney U test to define significance among two groups, while Kruskal-Wallis test was used to verify the significance between more than two groups. The normal distribution was checked via Shapiro-Wilk test and Gaussian distribution; and all data was passed normality test ($\alpha=0.05$), (GraphPad Software, Inc., San Diego, CA, USA). Spearman correlation was used to define the correlation between the tested parameters. *P*-value was set at <0.05 to define statistical significance.

TABLE 1. Paraovarian cyst (POC) buffaloes with description for the associated pathological conditions in the genital system.

Numbers of animals with POC	Associated pathological conditions
1	Vaginitis
2	Mild cervicitis
3	Mild endometritis and oovaritis and salpingitis
1	Mild endometritis, ovarian tumour (22.7 x 18.8 mm)
2	Enlarged valva, cervicitis, follicular cyst (30.8 x 23.3 mm)
1	Pyosalpinx and uterine adhesions
3	Vaginitis, chronic cervicitis, pyosalpinx
2	Chronic fibrosis of cervix
3	Mild endometritis

Results

Ultrasound findings

Representative ultrasound images of buffaloes had POC in presence of CL or absence is shown in (Fig. 1 and 2). Ovarian changes in animals demonstrated paraovarian cyst versus normal reproductive physiological statuses (cyclicality

and pregnancy) is shown in (Table 2). Analysis of the obtained data revealed, as expected, that the paraovarian cysts size, follicular number ($P=0.845$) and corpus luteum size ($P=0.161$) were not statistically varied, although dominant follicle size tended to be significantly ($P=0.069$) differed between groups.

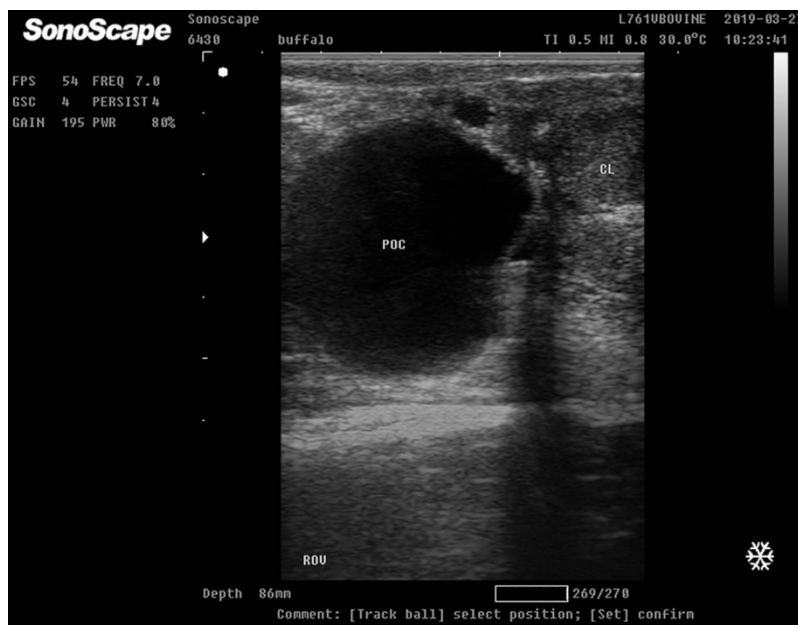

Fig. 1. Representative ultrasonogram of paraovarian cyst in buffalo heifer nearby the ovary that presented corpus luteum. Paraovarian cyst (POC) appeared as a large translucent anechoic cavity. The corpus luteum (CL) showed a varying degree of heterogeneity.

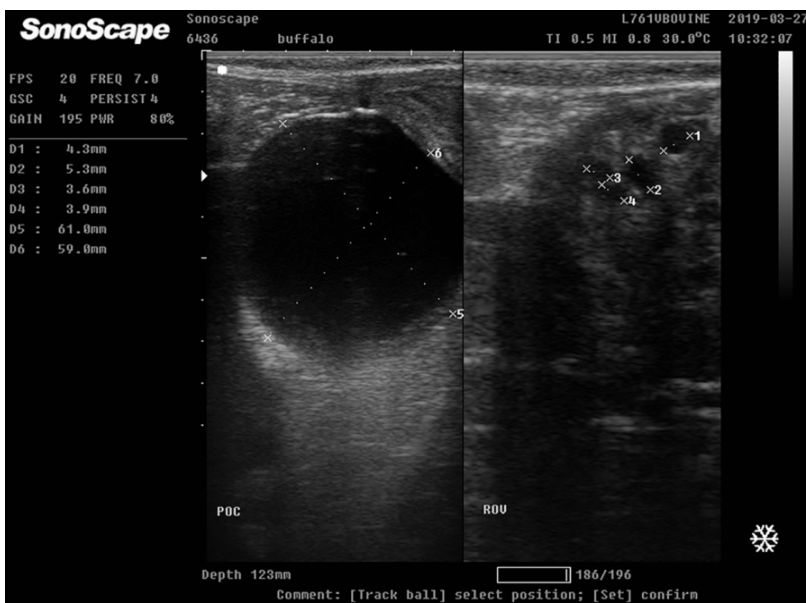


Fig. 2. Representative ultrasonogram of paraovarian cyst in buffalo heifer nearby the ovary that presented growing follicles. Paraovarian cyst (POC) appeared as a large translucent anechoic cavity, and the growing follicle appeared smaller in size circumscribed anechoic areas within the ovarian parenchyma.

TABLE 2. Ovarian changes in buffaloes with paraovariancyst.

	Paraovarian cyst		Normal physiological conditions			P value
	Without CL (POC-CL)	With CL (POC+CL)	Follicular	Luteal	Pregnant	
Paraovarian cyst size	49.23±6.01	30.50±5.49	--	--	--	0.10*
Dominant follicle size (mm)	7.2±0.96	14.90±2.31	16.5±1.32	8.71±2.51	7.95±0.26	0.069
Follicle number on ovaries	3.0±0.9	2.3±0.3	3.0±0.6	3.0±0.5	2.3±0.6	0.845
Size of CL (mm)	--	21.40±1.44	--	20.33±0.55	23.3±0.98	0.161

* Mann Whitney test

Alterations in steroidal hormones, antioxidants, and serum cell-free RNA levels

Ovarian steroid hormone analysis (Table 3) showed significant ($P= 0.003$) difference in progesterone level between non-luteal (POC-CL and follicular phase) and luteal (POC+CL, cyclic CL, pregnancy). In contrary, estradiol variances between these groups did not reach statistical level ($P= 0.160$).

The level of antioxidants (Table 4) showed marked differences in MDA and SOD and total serum proteins ($P< 0.009$, 0.013, and 0.012, respectively), heifers having in paraovarian cyst compared to cyclic (follicular and luteal phases) and pregnant buffaloes. Cases with POC in the absence of CL (POC-CL) had lower MDA levels than pregnant cases (5.99±0.35 and 13.70±0.63 nmol/mL, respectively). Buffaloes had POC in the presence of CL (POC+CL) had higher SOD activity than luteal and pregnant cases (226.70±1.44U/ml vs. 166.90±3.47 and 168.20±1.29 U/ml, respectively). Total protein level was lower in POC+CL than those in follicular phase (3.69±0.39 and 8.39±0.31 g/dl, respectively).

Although serum free RNA not significantly varied between POC cases and physiological conditions (Fig. 3), it was significantly ($P= 0.006$) lower during pregnancy than follicular phase (7.58±0.34 vs. 14.92±0.44 ng/μl, respectively).

Discussion

Ovarian cysts are classified into intraovarian cysts, the cysts within the ovary, and periovarian (paraovarian) cysts that are outside to the ovary.

The POC are recorded in buffalo post-slaughter [34]. However, in our study; the POC was diagnosed in repeat-breeder buffalo heifers, by means of ultrasonography, and the incidence was 4.5%. Large POC may predispose for ovarian torsion and rupture of broad ligament. Concurrently, it was recorded that POC at an incidence of 4.4% of the examined slaughtered buffaloes [15]. Moreover, Vala [8] showed that the incidence of POC was the highest among ovarian affections in culled infertile buffaloes (13.74%), while luteal and follicular cysts incidences were the lowest (1.53 and 0.76%, respectively).

Former studies differed in the interpretation of the significance of POC on animal reproduction. While some of them [15] declared its non-significant effect on female fertility and its interference only with the diagnosis of ovarian cyst, others [10] showed that the fertility is distressed in case of the POC when compressing the uterus to block the oviductal opening. In this study most of the POC cases were encountered in animals culled due to subfertility problems.

Ultrasonographic measuring of POC showed that its size varied from 14.16 mm to 61.00 mm with mean values of 49.23±6.01 and 30.50±5.49 mm in case of CL presence or absence, respectively. This finding was in accordance with former studies showed that POC of a few millimetres in diameter are incidental findings in slaughtered buffaloes [18], though it may vary in size from 1 to 5 cm in diameter [9]. Bohiltea et al. [36] indicated the use of ultrasound exam for paraovarian cyst diagnosis that appeared as a round or oval well-defined cystic mass, located close to the ipsilateral ovary, but clearly separated.

TABLE 3. Effect of paraovarian cyst on ovarian steroid hormones in buffaloes.

	Paraovarian cyst		Normal physiological conditions			P value
	Without CL (POC-CL)	With CL (POC+CL)	Follicular	Luteal	Pregnant	
P4 Conc. (ng/ml)	0.419±0.004 ^b	4.333±0.066 ^{ab}	0.293±0.049 ^b	2.597±0.264 ^{ab}	4.662±0.103 ^a	0.003
E2 Conc. (pg/ml)	2.668±0.063	4.077±0.921	5.440±0.385	3.080±0.246	3.212±0.496	0.160
P4/E2 ratio	0.155±0.005 ^{ab}	1.267±0.303 ^{ab}	0.053±0.012 ^b	0.857±0.127 ^{ab}	1.540±0.152 ^a	0.006

Kruskal-Wallis test.

Small different letters in the rows denote significantly ($P < 0.05$) between groups

TABLE 4. Effect of paraovarian cyst on antioxidant parameters in buffaloes.

	Paraovarian cyst		Normal physiological conditions			P value
	Without CL (POC-CL)	With CL (POC+CL)	Follicular	Luteal	Pregnant	
TAC (mM/L)	1.56±0.01	1.49±0.04	1.49±0.12	1.52±0.14	1.52±0.03	0.718
MDA (nmol/mL)	7.71±1.02 ^{ab}	5.99±0.35 ^b	9.61±0.59 ^{ab}	6.55±0.29 ^{ab}	13.70±0.63 ^a	0.009
GPx (mU/ml)	46.30±2.01	41.36±1.18	45.05±0.58	44.27±0.37	44.07±0.68	0.218
SOD (U/ml)	226.70±1.44 ^a	199.60±15.19 ^{ab}	173.30±4.41 ^{ab}	166.90±3.47 ^b	168.20±1.29 ^b	0.013
Total protein (g/dl)	3.69±0.39 ^b	5.74±1.28 ^{ab}	8.39±0.31 ^a	7.54±0.29 ^{ab}	5.09±0.51 ^{ab}	0.012

Kruskal-Wallis test

Small different letters in the rows denote significantly ($P < 0.05$) between groups

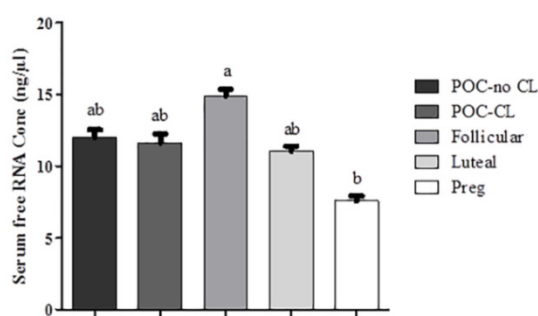


Fig. 3. The concentration of serum cell-free RNA in buffaloes demonstrated paraovarian cyst compared to control animals. Values (Mean±SE) with different letters were significantly different at $P < 0.05$ (Kruskal-Wallis test).

The interrelationship between examined parameters were analyzed and presented in (Table 5). There was a significant correlations between POC and GPx activity ($r=0.586$, $P < 0.05$) and CL size ($r=0.817$, $P < 0.01$), but negative correlation with dominate follicle size ($r=-0.503$, $P < 0.01$).

TABLE 5 . Spearman's correlations between antioxidant parameters, steroid hormones, and ovarian activity in buffaloes.

	TAC	GPx	SOD	Protein	P4	E2	P4/E2 ratio	RNA	Dominant folliclesize (mm)	Follicle number on ovaries	CL size (mm)	Size of paraovarian cyst (mm)
MDA	0.168	-0.006	-0.443	0.078	0.311	0.058	0.202	-0.352	-0.074	-0.253	0.226	-0.25
TAC		0.022	0.435	-0.277	-0.045	-0.197	-0.065	-0.021	0.019	-0.497	0.209	0.296
GPx			-0.007	0.121	-0.295	0.009	-0.368	0.085	-0.154	0.454	-0.075	.586*
SOD				-.403*	-0.338	-0.246	-0.324	0.424	0.141	-0.301	0.084	0.321
Protein					-0.32	.725**	-0.352	0.382	0.464	0.242	-.879**	-0.714
P4						-0.238	.916**	-.845**	-0.222	-0.267	0.653	-0.335
E2							-.474*	0.398	.694**	0.022	-.753*	-0.739
P4/E2								-.810**	-0.311	-0.212	.787*	-0.148
RNA									0.419	0.227	-.828**	0.071
DF size										-0.295	-0.155	-.503*
Fol. no.											-0.487	0.63
CL size												0.817**

DF: Dominant Follicle. *;Correlation is significant at the 0.05 level (2-tailed). **;Correlation is significant at the 0.01 level (2-tailed).

We monitored for the first time some biochemical changes in association with its presence including lower MDA, total protein, and an increase in SOD. Antioxidants are responsible for the balance between reactive oxygen species production and clearance. The disturbance in this balance can persuade pathological ovarian dysfunction, which can ultimately influence fertility. Biochemical alternations associated with POC was first to be indicated herein where MDA and total proteins levels were lower than its corresponding values in pregnancy and follicular phase, respectively, while SOD activity was higher than luteal and pregnancy. Moreover, total serum protein levels were negatively correlated with SOD. POC size was positively correlated with GPx activity ($r=0.586$, $P<0.05$) and negative correlated with dominate follicle size ($r=-503$, $P<0.01$). At the same time, total serum protein was positively correlated with E2. This might indicate that high SOD possibly will lower total protein and E2. The E2 is a product of follicles while it grow and responsible for the expression of the signs of heat. Former studies indicated that SOD had inhibitory impacts on estrogen synthesis by inhibiting FSH-induced aromatase activity in cultured granulosa cells that occurred at post-FSH receptor sites in rodent granulosa cells *in vitro* [37]. Taken together, POC might predispose to ovarian dysfunction and low expression signs of heat mediated through oxidative stress. Although this relationships were not proven but our data might enthuse this assumption and explain why POC is largely recorded in culled animals, due to subfertility problems. It has been proposed that decreased antioxidant defence systems preludes to pathological consequences include many reproductive diseases such as cystic ovaries, endometriosis, and unexplained infertility [19].

In our study, the concentration of serum cell-free RNA was not significantly varied between POC cases and physiological conditions. This may indicate that POC has no a clear effect on the concentration of serum cell-free RNA, in the studied animals. Although, it was shown clear alterations at the expression profile of serum cell-free RNA in patients with some infertility problems such as; endometriosis and POC [25], this may indicate that POC might affect the expression profile of serum cell-free RNA, not its concentrations. Here in the current study, we did not go further for expression profile, due to limitation in our facility. We also noticed that the serum cell-free RNA level was significantly lower

during pregnancy than follicular phase. This could be resulted from contribution of serum cell-free RNA in placental formation during pregnancy progression [38].

Conclusions

POC has mild or no effect on buffalo fertility as no clear changes was found in steroid levels as well as serum cell-free RNA concentration. However, we observed alterations in some antioxidant parameters, which might interfere with ovarian functions in the examined buffalo cases.

Acknowledgments

This work was financially supported by Grant-in-Aid from the National research centre, Egypt.

Conflict of interest statement

None.

Funding statement

Supplemented financially from National Research Center, Internal projects.

References

- Purohit, G.N. Recent developments in the diagnosis and therapy of repeat breeding cows and buffaloes. *Perspectives in Agriculture, Veterinary Science, Nutrition and Natural Resources*, **3**, 3-34 (2008).
- Saraswat, C.S. and Purohit, G.N. Repeat breeding: Incidence, risk factors and diagnosis in buffaloes. *Asian Pacific Journal of Reproduction*, **5**(2), 87-95 (2016).
- Ali, A., Abdel-Razek, A.Kh., Derar, R. and Sehata, S.H. Forms of reproductive disorder in cattle and buffaloes in middle Egypt. *Reprod. Domest. Anim.* **44**, 580-586(2009).
- Dwivedi, J.N. and Singh, C.M. Studies on the pathology of female reproductive organs of Indian buffaloes. 1. Ovarian abnormalities. *Indian J. Anim. Health*, **10**, 27-36(1971).
- Kaikini, A.S. Studies on bovine gynecology-gonads and reproductive tract of Berari buffaloes. PhD Thesis Punjab Rao Agricultural University, Akola, Maharashtra India (1974).
- Potekar, A.M., Deshpande, B.R. and Pargaonkar, D.R. Note on ovarian abnormalities in Indian buffaloes. *Indian J. Anim. Sci.*, **52**, 951-954(1982).
- Jeevanajyothi, B.S., SadasivaRao, K. and Soloman Raja, K.G. Reproductive disorders in buffaloes of Ranga Reddy district of Andhra Pradesh. *Indian J. Anim. Res.*, **37**, 107-109 (2003).

8. Vala, K.B. Studies on anatomical causes, bovine infertility, genital organs, she-buffaloes. M. V. Sc. Thesis. Colleague of Veterinary Science and Animal Husbandry, Anand Agriculture Univ., Anand, India(2009).
9. Srinivasan, T.,Lakkawar, A., Varshney, K., Raju, S. and Thandavamurthy, C., Pathology of cystic ovarian degeneration in buffaloes.*International Journal of Livestock Research*,7(4),180-187 (2017).
10. Smith, K.C., Long, S.E. and Parkinson, T.J.Abattoir survey of congenital reproductive abnormalities in ewes. *Vet. Rec.*,**143**(25), 679 – 685 (1998).
11. Azawi, O.I. and Ali, A.J. A study on the prevalence of pathological abnormalities of the ovaries and oviducts diagnosed at post mortem of buffaloes in Mosul.*Buffalo Bulletin*,**34**, Article no. 1(2015).
12. Carleton, C.L. Clinical Examination of the Nonpregnant Equine Female Reproductive Tract.Chapter 9. In: Current Therapy in Large Animal. 2nd ed. Youngquist RS and Threfall WR (Eds.).Saunders Elsevier; Inc, Westline Industrial Drive St. Louis, Missouri, USA.PP. 76(2007).
13. Mann, G.S., Sellars, M.E.K. and Sidhu, P.S.The paediatric uterus, ovaries and testes.Chapter 72. In: Clinical Ultrasound (Third Edition). Allan PL, Baxter GM and Weston MJ (Eds.).Volume 2. PP. 1468-1496 (2011).
14. Jubb, K.V.F., Kennedy, P.C. and Palmer, N.C. Pathology of Domestic Animals, 5th edition. Saunders Elsevier: Philadelphia, PA (2007).
15. Azawi, O.I., Ali, A.J. and Lazim, E.H. Pathological and anatomical abnormalities affecting buffalo-cows reproductive tracts in Mosul.*Iraqi Journal of Veterinary Sciences*.**22**(2), 59-67(2008).
16. Long, S.E. Some pathological conditions of the reproductive tract of the ewe. *Vet. Rec.* 106(8), 175–177(1980).
17. Dawood, K.E.Pathological abnormalities of the reproductive tracts of ewes in Basra, *Iraq. Vet. Rec.***166**(7), 205–207(2010).
18. Mittal, D.,Garg, U.K. and Jatav, G.P. Prevalence of different pathological affections of ovaries in buffaloes (*Bubalus bubalis*) in Malwa region of Madhya Pradesh.*Buffalo Bulletin*, **29**, 39-42 (2010).
19. Wang, S., He, G., Chen, M., Zuo, T., Xu, W. and Liu, X.The Role of antioxidant enzymes in the ovaries.*Oxidative Medicine and Cellular Longevity*, 1, 1-14(2017).
20. AbdElHameed, A.R., Mahmoud, K.Gh.M., Nawito, M.F., Sosa, A.S.A. and Ezzo, O.H. Progesterone concentration, oxidants and antioxidants indices in singleton and multiple bearings ewes and does. *Bioscience Research*, **15**(4), 3881-3887(2018).
21. Kandiel M., M.M., Heba, M. El-Khaiatand Mahmoud,K.Gh.M., Changes in some hematobiochemical and hormonal profile in Barki sheep with various reproductive statuses.*Small Ruminant Research*, **136**, 87-95(2016).
22. Moga, M.A., Bălan, A., Dimienescu, O.G., Burtea, V., Dragomir, R.M. and Anastasiu, C.V. Circulating miRNAs as Biomarkers for Endometriosisand Endometriosis-Related Ovarian Cancer.*J. Clin. Med.*, **8**, 735(2019).
23. Mi, S., Zhang, J., Zhang, W. and Huang, R.S.Circulating MicroRNAs as Biomarkers for Inflammatory Diseases.*Microrna*, **2**(1), 64–72 (2013).
24. Max, K.E.A., Bertram, K., Akat, K.M.,Bogardusa, K.A., Lia, J., Morozova, P., Ben-Dov, I.Z., Li, X., Weiss, Z.R., Aziziane, A., Sopeyina, A., Adamidia, T.C., Williams, Z. and Tuschl, T. Human plasma and serum extracellular small RNA reference profiles and their clinical utility. *Proc.Natl.Acad. Sci., USA*, **115**(23), E5334- E5343 (2018).
25. Xu, X.X., Jia, S.Z., Dai, Y., Zhang, J.J., Li, X.Y., Shi, J.H., Leng, J.H. and Lang, J.H. Identification of Circular RNAs as a Novel Biomarker for Ovarian Endometriosis. *Chin. Med. J.*,**131**, 559-566 (2018).
26. Wang, D., Luo, Y. and Wang, G. and Yang, Q. Circular RNA expression profiles and bioinformatics analysis in ovarian endometriosis. *Mol. Genet. Genomic Med.*, **7**, e756 (2019).
27. Kähn, W. Veterinary reproductive ultrasonography. 1st ed. SchlüterscheAuflage: vergriffen, keine Neuauflage. pp. 122-131 (2004).
28. DesCôteaux, L. Practical Atlas of Ruminant and Camelid Reproductive Ultrasonography. DesCôteaux L. (editor-in chief).Gnemmi G. and Colloton J. (associate editors). Blackwell Publishing: State Avenue, Ames, Iowa 50014-8300, USA. pp. 198(2010).
29. Koracevic, D., Koracevic, G., Djordjevic, V.S., Andrejevic, S. and Cosic, V.V. Method for the measurement of antioxidant activity in human fluids. *J. Clin. Pathol.*, **54**, 356–361 (2001).
30. Ohkawa H, Ohishi W. and Yagi K.Assay for lipid peroxides in animal tissues by thiobarbituric acid reaction.*Anal. Biochem.*, **95**, 351–358 (1979).

31. Paglia, D.E. and Valentine, W.N. Studies on the quantitative and qualitative characterization of erythrocyte glutathione peroxidase. *J. Lab. Clin. Med.*, **70**, 158-169(1976).
32. Nishikimi, M., Rao, A. and Yagi, K. The occurrence of superoxide anion in the reaction of reduced phenazinemethosulphate and molecular oxygen. *Biochem. Biophys. Res. Commun.*, **46**, 849-854 (1972).
33. Gorna, A.C., Bardawill, C.J., Davia, M.M. Determination of serum proteins by means of the biuret reaction. *J. Biol. Chem.*, **177**, 751-766 (1949).
34. Saxena, G., Rani, S., Danodia, H.K. and Purohit, G.N. Pathological conditions in genital tract of female buffaloes (*Bubalus bubalis*). *Pakistan Vet. J.*, **26**(2), 91-93(2006).
35. Foster, R.A. Female Reproductive System and Mammal. In: Pathologic Basis of Veterinary Disease (Sixth Edition). *Zachary J.F.*, 1147-2017(1193).
36. Bohiltea, R.E., Cirstoiu, M.M., Turcan, N. and Ionescu, C.A. Ultrasound diagnostic of mesonephric paraovarian cyst-case report. *Journal of Medicine and Life*, **9**(3), 280-283(2016).
37. LaPolt, P.S. and Hong, L.S. Inhibitory effects of superoxide dismutase and cyclic guanosine 3,5-monophosphate on estrogen production in cultured rat granulosa cells. *Endocrinology*, **136**, 5533-5539 (1995).
38. Tsang, J.C.H., Vong, J.S.L., Ji, L., Poon, L.C.Y., Jiang, P., Lui, K.O., Ni, Y.B., To, K.F., Cheng, Y.K.Y., Chiu, R.W.K. and Lo, Y.M.D. Integrative single-cell and cell-free plasma RNA transcriptomics elucidates placental cellular dynamics. *PNAS*, **114**(37), E7786-E7795 (2017).

التكيس خارج المبيض في عجلات الجاموس المتكررة الشياح: الموجات فوق الصوتية ، مضادات الأوكسدة وعلامات الحمض النووي الريبوزي في المصل الخالي من الخلايا

محمد محمود مصطفى قنديل¹ ، كريمه غنيمي محمود²، سالى ابراهيم³، عبدالعزيز مصطفى صقر⁴، محمد حجازى⁵، أمال رياض عبد الحميد⁶ وأحمد سيد عبد الرحيم سوسة⁷
¹جامعة بنها- كلية الطب البيطري- قسم التوليد والتناسل والتلقيح الاصطناعي - القليوبية - مصر.
²المركز القومي للبحوث- قسم تكاثر الحيوان والتلقيح الصناعي - الجيزة - مصر.
³مركز البحوث الزراعية -معهد بحوث الإنتاج الحيواني - الجيزة - مصر.

هدفت هذه الدراسة إلى (1) تحديد حالة الجهاز التناسلي لعجلات الجاموس المتكررة الشياح بالموجات فوق الصوتية ، وكذلك (2) تحديد الاختلافات في هرمونات الستيرويد ، والمؤشرات الحيوية للتأكسد ، والحمض النووي الريبوزي في المصل الخالي من الخلايا. تم فحص الحيوانات المستبعدة من 400 بقرة في محطة تربية العجلات بالموجات فوق الصوتية ، وجمع عينات دم. تم تشخيص العجلات بالموجات فوق الصوتية على أنها تكيس خارج المبيض (ن = 18) وكانت مرتبطة بحالات مرضية تناسلية وتم مقارنتها مع مجموعات ضابطة في الطور الجريبي (ن = 6) ، الأصفر (ن = 6) ، والحمل المبكر (ن = 10). ظهرت التكيسات ككتل محددة عديمة الصدى تقع بالقرب من المبيض ولكنها منفصلة عنه. لم يتأثر عدد الجريبات وحجم الجسم الأصفر والحمض النووي الريبوزي المعزول من المصل والستيرويدات المبيضية بوجود التكيسات خارج المبيض على الرغم من أن حجم الجريبة السانده يميل إلى أن يكون أقل (P = 0.069) في غياب الجسم الأصفر. كما ان الحالات المصابة بوجود التكيسات خارج المبيض وغياب الجسم الأصفر كان لديها مستويات MDA أقل من العوامل. كان للعجلات ذات التكيسات خارج المبيض مع وجود الجسم الأصفر نشاط SOD أعلى من الحالات الجسم الأصفر والعوامل. كان تركيز البروتينات الكلية في المصل أقل في العجلات ذات التكيسات خارج المبيض مع وجود الجسم الأصفر مما كانت عليه في المرحلة الجرابية. كانت هناك علاقة إيجابية معنوية بين حجم الحويصلة ونشاط GPX وحجم الجسم الأصفر، ولكن هناك ارتباطات سلبية مع حجم الجريبات السانده. والخلاصة أن التكيسات خارج المبيض تتداخل مع وظيفة المبيض ، عن طريق التغييرات في مستويات مضادات الأوكسدة.

الكلمات الدالة: التكيس خارج المبيض. عجلات الجاموس المتكررة الشياح ؛ الموجات فوق الصوتية. مضادات الأوكسدة. الحمض النووي الريبوزي في المصل